



## PATIENT PRESENTING CLINICAL SIGNS

London Germain Chronic congestion/ URI symptoms since owner acquired her as a kitten. Currently pet has bilateral mucoid nasal discharge and is open mouth breathing/ swallowing hard. FeLV/ FIV negative. Non-response to Doxycycline, Azithromycin, Clavamox and prednisolone. Samples taken for the oropharynx and conjunctiva for viral PCR, and from the nasal passages for bacterial C/S.

## Feline COMPUTED TOMOGRAPHIC STUDY OF THE HEAD

Plain and post contrast studies are available for review.

## BREED COMPUTED TOMOGRAPHIC FINDINGS

DSH Severe bilateral destructive rhinitis characterized by extensive fluid accumulation, mucosal swelling and turbinate lysis within both nasal passages is noted.

SEX The cribriform plate remains intact.

FI The frontal sinuses are within normal limits.

AGE The nasopharynx is occupied by an ovoid well-delineated uniformly soft tissue attenuating mass with polypoid extension from the left middle ear. Mass measurements are ~ 2 cm x 1 cm x 1 cm.

2yr The left tympanic bulla is markedly abnormal with fluid attenuating content and irregular bony margins. Regional meningeal thickening and enhancement is noted adjacent to the left tympanic bulla. Mild changes in the right tympanic bulla are noted consistent with mild chronic otitis media.

## INTERPRETED BY

Nele Eley (Ondreka),  
DVM Dr. med. vet.,  
DipECVDI

Bilateral otitis externa left side more severely affected than the right is noted with thickened epithelial lining.

Moderate bilateral submandibular and retropharyngeal lymphadenomegaly is seen.

## HOSPITAL NAME COMPUTED TOMOGRAPHIC DIAGNOSIS

Wilson Veterinary  
Hospital

- Severe bilateral destructive rhinitis.
- Bilateral otitis externa left more severe than right.
- Chronic left otitis media with nasopharyngeal polyp formation and evidence of intracranial extension.
- Mild right-sided otitis media.
- Reactive regional lymphadenopathy.

## REFERRING VET

Dr Nicholas Vitale

## INVOICE INTERPRETATION OF FINDINGS & FURTHER RECOMMENDATIONS

22986

The severe destructive rhinitis likely accounts for the chronic congestion, stertor and nasal discharge. The etiology may be chronic bacterial, fungal, viral induced and less likely non-infectious such as lymphoplasmacytic. The left nasopharyngeal polyp is a consequence of chronic left-sided otitis media. The middle ear inflammation presents evidence of intracranial extension with reactive regional meningiopathy.

## DATE

11/18/2025



**PATIENT**

London Germain

The regional lymphadenopathy is most likely reactive. Removal or debulking of the left nasopharyngeal polyp is recommended with evaluation of the tympanic bulla especially the left tympanic bulla and potential surgical management if indicated. C/S testing, supportive management for otitis externa and aggressive medical treatment addressing the potential intracranial extension of the left-sided otitis media are recommended.

**SPECIES**

Feline

**BREED**

DSH

**SEX**

FI

**AGE**

2yr

**INTERPRETED BY**

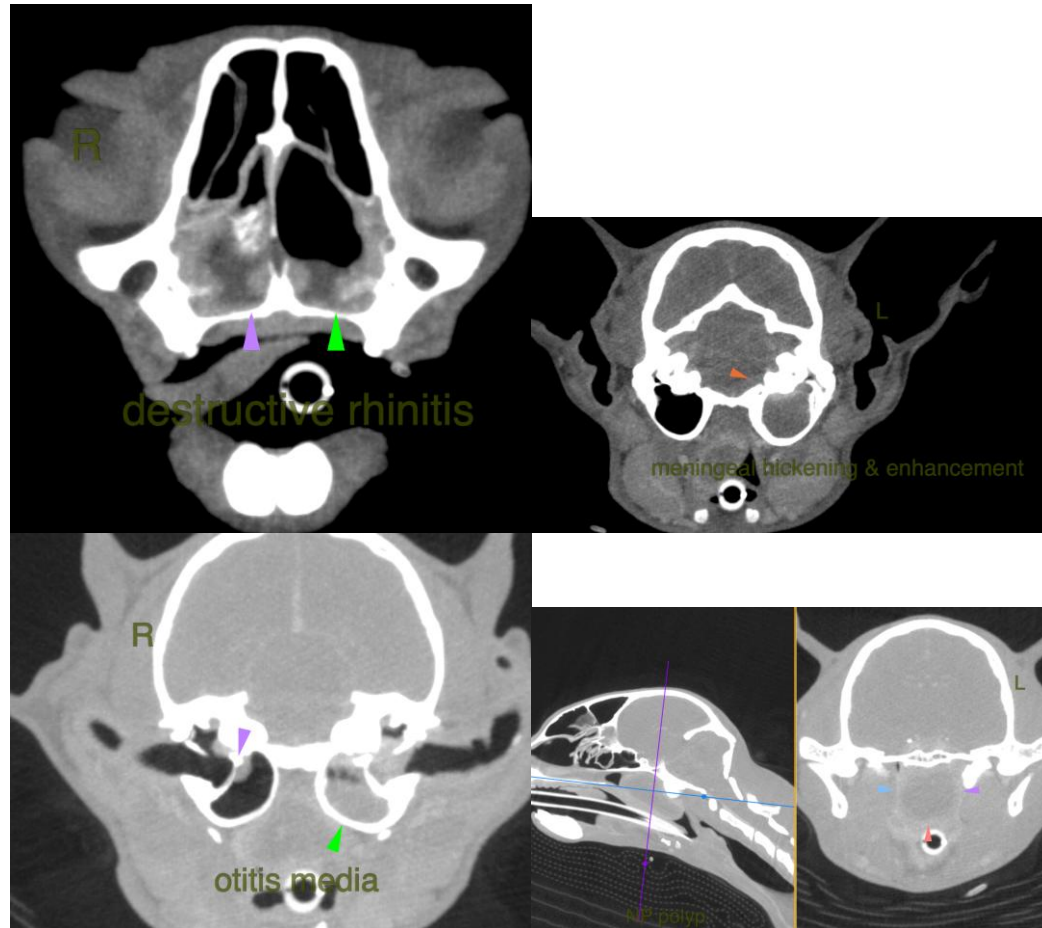
Nele Eley (Ondreka),  
DVM Dr. med. vet.,  
DipECVDI

**HOSPITAL NAME**

Wilson Veterinary  
Hospital

**REFERRING VET**

Dr Nicholas Vitale



The information and recommendations provided are based on the images presented by the referring veterinarian. No evaluation can be communicated regarding pathology that was not visible in the image/video clips provided.

**INVOICE**

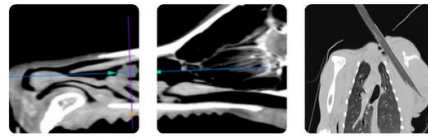
22986

Thank you for this referral. If the clinical or image interpretation does not parallel your findings or if I can be of any further assistance please contact me.

**DATE**

11/18/2025

Nele Eley (Ondreka), DVM, Dr. med. vet., DipECVDI  
European Specialist in Veterinary Diagnostic Imaging, Cert. Radiology,  
Senior lecturer University of Giessen/Germany, Veterinary Faculty, Department of Radiology.



**PATIENT** [info@sonopath.com](mailto:info@sonopath.com)

London Germain

**SPECIES**

Feline

**BREED**

DSH

**SEX**

FI

**AGE**

2yr

**INTERPRETED BY**

Nele Eley (Ondreka),  
DVM Dr. med. vet.,  
DipECVDI

**HOSPITAL NAME**

Wilson Veterinary  
Hospital

**REFERRING VET**

Dr Nicholas Vitale

**INVOICE**

22986

**DATE**

11/18/2025